

PREVALENCE OF *Cryptosporidium* AND *Eimeria* INFECTIONS IN DROMEDARY (*Camelus dromedarius*) IN ABATTOIR OF MASHHAD, IRAN

Hassan Borji, Gholamreza Razmi, Ahmad Reza Movassaghi,
Abol Ghasem Naghibi and Mohsen Maleki

Department of Pathobiology, School of Veterinary Medicine, Ferdowsi University of Mashhad, Mashhad, Iran

ABSTRACT

This research was conducted to determine the prevalence of *Eimeria* spp. and *Cryptosporidium* spp. oocysts in camels. Faecal samples of 306 dromedaries (*Camelus dromedarius*) in abattoir of Mashhad, a city in north east Iran and the capital of Khorasan province between October 2007 and September 2008 were analysed for *Cryptosporidium* oocysts by microscopic examination of smears stained by modified Ziehl-Neelsen technique. The parasite was detected in 6 camels (1.9%). The same samples were examined by saturated solution of sodium nitrate floatation technique for *Eimeria* oocysts. During the laboratory examination of faecal samples, *Eimeria* spp. oocysts were identified in 57 (18.62%) of the dromedaries examined. *Eimeria dromedarii* was the most prevalent and *Eimeria cameli* the least. The prevalence of *Eimeria* was highest during the winter ($p < 0.05$). This is the first report of cryptosporidiosis in dromedary camel (*Camelus dromedarius*) in Iran.

The mucosae of the ileum, caecum and colon of infected camels were oedematous, congested and ulcerated. Histopathological examination of this ileum revealed distended, disorganised villi and crypts due to developmental stages of *Eimeria*, and moderate to severe inflammatory reaction was seen mainly by infiltration of eosinophils and lymphocytes.

Key words: camel, cryptosporidium, eimeria, mashhad, Iran

Cryptosporidiosis is a waterborne protozoan disease of public health significance. *Cryptosporidium* spp. is a protozoan parasite that can cause gastrointestinal illness in a wide variety of mammals, including humans, cattle, sheep, goat, pig, horses and camels world-wide (Fayer *et al*, 2000). For camel farms, *Cryptosporidium* has become a concern not only because of the direct economic losses associated with the infection, but also from a public health perspective because of the potential for environmental contamination with *Cryptosporidium* oocysts. It is well known that most data on the prevalence of *Cryptosporidium* infection in animals concern cattle. In comparison, there is less information on the occurrence of cryptosporidiosis in dromedary camel (Soltane *et al*, 2007).

Eimeria spp. is the most economically important protozoan pathogens of animals which causes coccidiosis. Several species of coccidia have been reported in camelids (Soulsby, 1982). No cross-transmission studies between camelids and other domestic animals have been reported. Reported clinical signs of coccidiosis in South American

camelids include anorexia of a few days duration, sudden death, and diarrhoea (Chigerwe, 2007). However, published diagnosis in prevalence rate of *Eimeria* spp. among camels are rare (Chineme, 1980, Hussein *et al*, 1987; Yagoub, 1989; Kinne and Wernery, 1997; Partani *et al*, 1999; Whitehead and Anderson, 2006). In Iran, few studies have been carried out to determine the prevalence of *Eimeria* spp infection in camel (Yakhchali and Cheraghi, 2007).

Hence, the major objective of the present study was to determine the recent prevalence and pathological lesion of *Eimeria* spp and *Cryptosporidium* in dromedary camel in Iran.

Materials and Methods

This study was conducted on 306 dromedary camels of different age and sex. Camel slaughtered in Mashhad abattoir, a city in northeast Iran during October 2007 to September 2008. After slaughtering of the dromedaries, faecal samples were collected directly from the rectum and put in a sterile plastic bag and were taken to laboratory within a few hours of collection and were stored at 4°C.

SEND REPRINT REQUEST TO HASSAN BORJI [email: hborji@um.ac.ir](mailto:hborji@um.ac.ir)

Faeces were determined by the Clayton lane technique using saturated solution of sodium nitrate as the floating medium to assess oocyst per gram (Anon, 1977; Soulsby, 1982). To confirm the presence of *Cryptosporidium*, a fraction of each faecal sample was smeared on a microscope slide and stained using a modified Ziehl-Neilsen technique (Henriksen and Pohlenz, 1981).

Oocysts were examined using an oil-immersion 100 X objective on a Leitz microscope. Species identification was based on oocyst size, shape, and internal structure.

The gastrointestinal organs of infected camels were examined for gross pathological changes. The gross damage was recorded. Tissue samples were collected, preserved in 10% formalin solution, processed and stained with Haematoxylin and eosin (Anon, 1984) and were examined histopathologically.

Statistical evaluation of results was done with, SPSS 15 (SPSS for Windows ver. 15 © SPSS Inc., USA). The Chi-square test was used to adjudge the effects of season along with their possible interactions with *Eimeria*.

Results

Out of the 306 of camels examined during the study period, 57 (18.62%) were shedding oocyst in their faeces (Table 1 and Table 2). Most of camels examined during the present survey had low to moderate oocysts per gram (OPG <30).

The result of Chi-square test implicated that the correlation between prevalence of the disease and season were statistically significant ($p < 0.001$). The prevalence of *Eimeria* infection was high in winter

Table 1. Seasonal prevalence of *Eimeria* oocyst recovered from dromedary in abattoir of Mashhad.

Season	Sample size	Infection number and rate
Spring	89	10(11.23%)
Summer	32	5(15.62%)
Fall	138	24(17.39%)
Winter	47	18(38.29%)
Total	306	57(18.62%)

Table 2. Protozoan parasites found in dromedary in abattoir of Mashhad (n=306).

Protozoa	The number of infected dromedary	Percentage
<i>Eimeria</i> spp.	57	18.62
<i>Cryptosporidium</i> spp.	6	1.96
Total	63	20.58

than other seasons (Table 1). *Cryptosporidium* spp. was identified in 6 (1.9%) of camels.

Gross lesions were seen mostly in the ileum, caecum and colon. The mucosae of the ileum, caecum and colon were oedematous, congested and ulcerated. The most prominent macroscopic lesions were multifocal thickening of the mucosa in the jejunum, ileum, caecum, and colon with severe haemorrhage (Fig 1). In cases with marked lesions, the gut lumina generally contained fibrin strands and varying amount of blood.

Histopathological examination of the ileum revealed distended, disorganised villi and crypts due to developmental stages of *Eimeria*, and moderate to severe inflammatory reaction mainly by infiltration of eosinophils and lymphocytes. The developmental stages of *Eimeria* included microgametocytes, macrogametocytes, mature and giant schizonts. The giant schizonts were easily discernible in histological sections of the small intestine (Fig 2). Affected crypts were disorganised or obliterated due to the growth of the large schizonts. Villi were short, blunt, or fused and the tips were ulcerated. Oedema of the lamina propria and blunting and erosion of the villi associated with goblet cell hyperplasia and haemorrhage were marked (Fig 3).

In large intestines, the ridges were blunt, rounded and coalesced or flattened. The intestinal mucosa was denuded, ulcerated, or completely destroyed. The lesions in the colon were patchy in distribution and generally less severe than those in the caecum. While some glands were denuded and lined by attenuated or cuboidal epithelium, others were long, tortuous and hyperplastic. Macro and microgamonts and oocysts were the main forms seen at this stage (Fig 4). The surface was ulcerated with neutrophils, eosinophils and necrotic debris. In some cases, there was almost total destruction of crypts in the mucosa.

Discussion

Prevalence and pathological lesions of *Eimeria* and *Cryptosporidium* of dromedary in Iran is scarcely reported. In the present work, 1 year abattoir survey determined the prevalence and seasonal incidence of *Cryptosporidium* and *Eimeria* spp. of camel.

In the present study, the prevalence of the *Eimeria* spp. infection in camel was 18.62%. These oocysts were identified as *Eimeria dromedarii*, *Eimeria cameli* and *Eimeria rajasthani*. Similarly, prevalence of *Eimeria* infection bactrian and dromedary camels in Miandoab region of Iran was 12.8% (Yakhchali

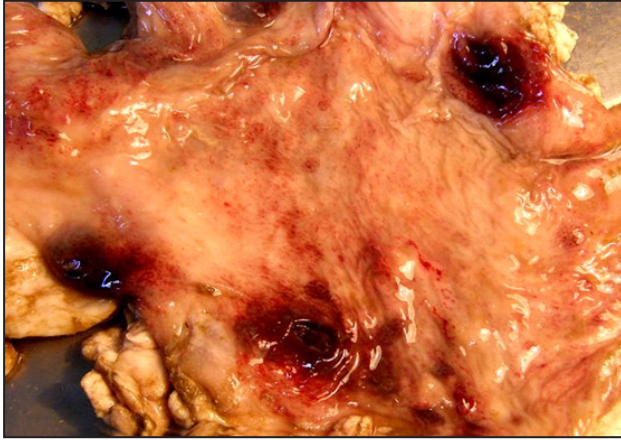


Fig 1. Thickened oedematous large intestine in affected camel shows multifocal haemorrhagic lesions caused by *Eimeria*.

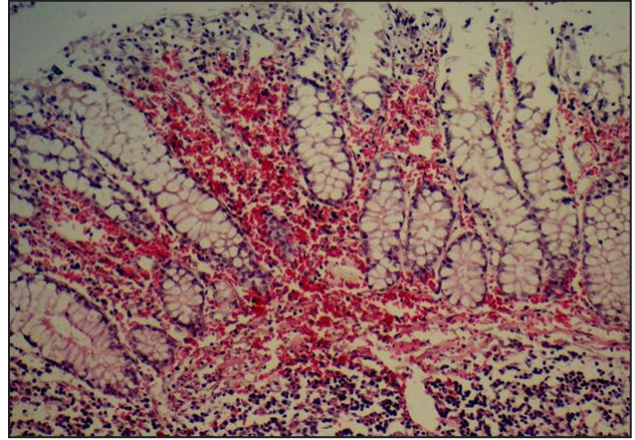


Fig 3. Epithelial necrosis with goblet cell hyperplasia and haemorrhage in the ileum of affected camel (Hematoxylin and Eosin, X 320).

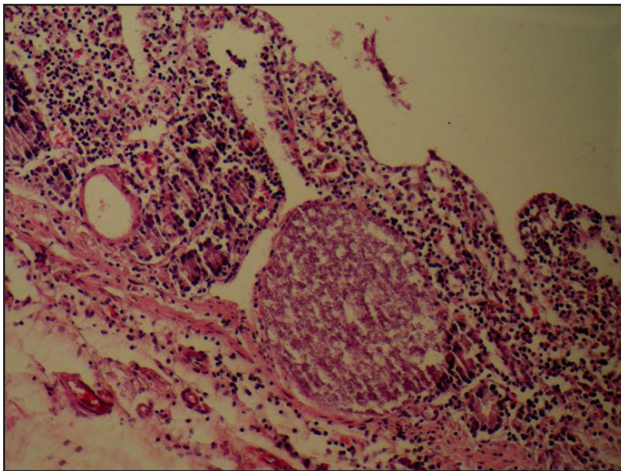


Fig 2. Giant schizonts in the lacteal of lamina propria and in the epithelium of Lieberkühn glands of ileum. There are ulcerated and fused villi with severe inflammatory reaction mainly by infiltration of eosinophils and lymphocytes. (Hematoxylin and Eosin, X 320).

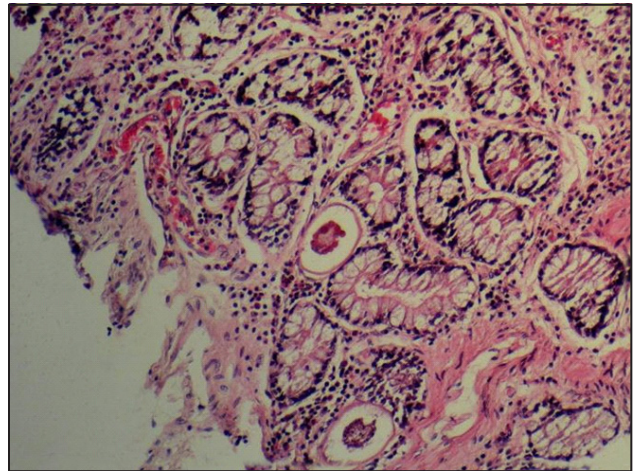


Fig 4. Cecal mucosa with necrosis and different stages of *Eimeria* infiltrated by inflammatory cells. X 160. (Hematoxylin and Eosin, X 320).

and Cheraghi, 2007). In previous study, *Eimeria bactriani*, *Eimeria rajasthani*, *Eimeria pellerdyi*, *Eimeria cameli* and *Eimeria dromedarii* were identified in camels. Prevalence of *Eimeria* infection in camels at Rajasthan was 29.19% (Partani *et al*, 1999). *Eimerian* species recorded were *Eimeria dromedarii*, *E. cameli*, *E. pellerdyi*, *E. rajasthani* and *E. nolleri*. Coccidial oocysts were detected in 40 (17.4%) out of 230 faecal samples obtained from camels in the Eastern Region of Sudan (Yagoub, 1989). These oocysts were identified as *Eimeria rajasthani*, *Eimeria dromedarii* and *Eimeria cameli*. Severe outbreak of camel coccidiosis in the United Arab Emirates is reported by Kinne and Wernery (1997). The observed haemorrhagic-eosinophilic enteritis associated with a massive invasion of *Eimeria cameli* suggests that this species is more pathogenic. The prevalence of *Eimeria* infections

in camels in Saudi Arabia was 41.6% and *Eimeria dromedarii* was the most prevalent and *Eimeria cameli* the least (Hussein *et al*, 1987; Kasim *et al*, 1985). The gross and histopathologic lesions caused by *Eimeria cameli* showed lesions in the small intestine which had swollen mucosa on which were numerous whitish-grey foci. Histologically, giant schizonts in various developmental stages were seen in the lamina propria of the jejunum. The associated inflammatory cellular response in these areas was predominantly mononuclear and eosinophilic in character (Chineme, 1980). Most of animals examined during the present survey had low to moderate OPG, suggesting that the infections were usually sub-clinical. However, the economical consequences of the sub-clinical infections are of importance. Sub-clinically infected animals appear normal outwardly, but possibly suffer

from reduced feed consumption, feed conversion and growth performance.

In the present study, oocysts of *Cryptosporidium* spp. were detected in 1.9% of 306 faecal specimens. Examination of faecal samples obtained from sheep, goats, horses, rabbits, camels, broiler chicken and turkeys in Tunisia showed the parasite in 10 sheep (11.2 %) and 9 broiler chickens (4.5 %) (Soltane *et al*, 2007). *Cryptosporidium* has been reported in South American camelids including alpacas (*Lama pacos*), llamas (*Lama glama*) and guanacos (*Lama guanicoe*) (Whitehead and Anderson, 2006, Stewart *et al*, 2005, Shapiro *et al*, 2005; Cebra *et al*, 2003; Bidewell and Cattell, 1998).

The occurrence of *Eimeria* and *Cryptosporidium* infection in camels has implications for epidemiology and transmission in animals and humans. These findings point to need for effective control programs, especially for young camels.

Acknowledgements

This work was supported by grant No. 709 from the Ferdowsi University of Mashhad which is gratefully acknowledged. Thanks are given to Mr. H. Eshrati for his technical assistance during data collection and Mr. M. Mohammad Nejad for taking pictures.

References

Anon (1977). Manual of Veterinary Parasitological Laboratory Techniques. Technical Bulletin No. 18, Ministry of Agriculture, Fisheries and Food, London. pp 129.

Anon (1984). Ministry of Agriculture, Fisheries and Food, Manual of Veterinary Investigation, Laboratory Techniques, Vol. 2. HMSO, London. pp 141-142, 162-176.

Bidewell CA and Cattell JH (1998). Cryptosporidiosis in young alpacas. *Veterinary Record* 142:287.

Cebra CK, Mattson DE, Baker RJ, Sonn RJ and Dearing PL (2003). Potential pathogens in feces from unweaned llamas and alpacas with diarrhoea. *Journal of the American Veterinary Medical Association* 223:1806-1808.

Chigerwe M, Middleton JR, Williams F 3rd, Tyler JW and Kreeger JM (2007). Atypical coccidiosis in South American camelids. *Journal of Veterinary Diagnostic Investigation* 19(1):122-5.

Chineme CN (1980). A case report of coccidiosis caused by *Eimeria cameli* in a camel (*Camelus dromedarius*) in Nigeria. *Journal of wildlife diseases* 16(3):377-380.

Fayer R, Morgan U and Upton SJ (2000). Epidemiology of *Cryptosporidium*: transmission, detection and identification, *International Journal for Parasitology* 30:1305-1322.

Henriksen SA and Pohlenz JF (1981). Staining of cryptosporidia by a modified Ziehl-Neelsen technique. *Acta Veterinaria Scand* 22(3-4):594-6.

Hussein HS, Kasim AA and Shawa YR (1987). The prevalence and pathology of *Eimeria* infections in camels in Saudi Arabia. *Journal of Comparative Pathology* 97:293-297.

Kasim AA, Hussein HS and Shawa YRA (1985). Coccidia in camels (*Camelus dromedarius*) in Saudi Arabia. *Journal of Protozoology* 32:202-203.

Kinne J and Wernery U (1997). Severe outbreak of camel coccidiosis in the United Arab Emirates. *Journal of Camel Practice and Research* 4:261-265.

Partani AK, Kumar Da and Manohar GS (1999). Prevalence of *Eimeria* infection in camels (*Camelus dromedarius*) at Bikaner (Rajasthan). *Journal of Camel Practice and Research* 6:69-71.

Shapiro JL, Watson P, McEwen B and Carman S (2005). Highlights of camelid diagnoses from necropsy submissions to the Animal Health Laboratory, University of Guelph, from 1998 to 2004. *Canadian Veterinary Journal* 46:317-318.

Soltane R, Guyot K, Dei-Cas E and Ayadi A (2007). Prevalence of *Cryptosporidium* spp. (Eucoccidiorida: Cryptosporiidae) in seven species of farm animals in Tunisia. *Parasite* 14:335-8.

Soulsby EJJ (1982). *Helminths Arthropods and Protozoa of Domesticated Animals* (7th Ed.), Bailliere Tindall, London.

Stewart WC, Pollock KGJ, Browning LM, Young D, Smith-Palmer A and Reilly WJ (2005). Survey of zoonoses recorded in Scotland between 1993 and 2002. *Veterinary Record* 157:697-702.

Whitehead CE and Anderson DE (2006). Neonatal diarrhea in llamas and alpacas. *Small Ruminant Research* 61:207-215.

Yagoub IA (1989). Coccidiosis in Sudanese camels (*Camelus dromedarius*): 1—First record and description of *Eimeria* spp. harboured by camels in the eastern region of Sudan. *Journal of Protozoology* 36:422-423.

Yakhchali M and Cheraghi E (2007). Eimeriosis in bactrian and dromedary camels in the Miandoab region, Iran. *Acta Veterinaria* 57:545-552.